

Retinoblastoma Registry Report – Hospital Kuala Lumpur Experience

R Jamalia*, R Sunder*, J Alagaratnam*, P P Goh**

*Ophthalmology Department, Hospital Kuala Lumpur, **Clinical Research Center, Third Floor, Dermatology Block Hospital Kuala Lumpur, 50586, Jalan Pahang, Kuala Lumpur, Malaysia

SUMMARY

Retinoblastoma is a childhood ocular cancer. The aim of this paper is to describe the clinical and epidemiological characteristics of patients with retinoblastoma in a major paediatric ophthalmology center in the country. Retrospective information was collected through the retinoblastoma registry. Late presentation with advanced staging is a major problem.

INTRODUCTION

Retinoblastoma is the most common ocular cancer in children. It usually occurs in children under 5 years of age. It is an aggressive tumour that can lead to loss of vision and, in extreme cases, death. Prognosis for vision and survival has significantly improved due to timely diagnosis and improved treatment methods. In developing countries, however, most of the case are detected at advanced stages¹⁻⁷.

There is no exact information regarding the frequency and clinical characteristics of retinoblastoma in Malaysia. The purpose of this paper is to report the result of the Retinoblastoma Registry, which was part of the Malaysia National Eye Database (NED). NED is a web-based surveillance, online data collection system on eye diseases and clinical performance in ophthalmology service⁸.

MATERIALS AND METHODS

This is a retrospective review of patients with retinoblastoma which was collected through the retinoblastoma registry. We evaluated records of patients diagnosed between 1 January 2004 till 31 December 2009, who were managed in Hospital Kuala Lumpur, the main referral center for retinoblastoma.

Patients were examined under general anaesthesia, including indirect ophthalmoscopy, fundus imaging (Retcam) and ultrasonography. Tumours were characterised using the International Intraocular Retinoblastoma Classification, IIRC (ABC Classification, Group A to E, Table I). Earlier data with Reese-Ellsworth Classification were reassigned with the ABC classification.

Patients were jointly managed by a team of paediatric ophthalmologists and oncologist. We enucleated eyes with advanced tumor with no visual potential, classified as Group E or Group D (in unilateral RB). Enucleated eyes were sent for pathological examination. Patients with tumors requiring

shrinkage (Group B to D) were treated with systemic chemotherapy (Vincristine, Etoposide and Carboplatin), with focal consolidation using 810nm diode laser and cryotherapy. Adjuvant systemic chemotherapy was also given to patients which enucleated eye showed extraocular infiltration in histopathological studies. Small tumors (Group A) received local laser or cryotherapy. Radiotherapy was given to extraocular RB and to tumors which were resistant to other treatment.

Data collected in the registry were demographic and clinical presentation at registration, modes of treatment, outcome (remissions and recurrences) and complication. Descriptive statistics for each variable were obtained.

RESULTS

Between January 2004 and December 2009, a total of 87 patients (117 eyes), diagnosed with retinoblastoma were seen in Hospital Kuala Lumpur. Figure 1 presents the number of patients per year. On average 14.5 new cases were seen per year. Fifty-four patients (62.1%) were male and 33 (37.9%) females with M:F ratio of 1.6:1.0. Majority of the patients were of Malay ethnicity (50 patients, 57.5%) followed by Chinese (16 patients, 18.4%) and Indians (eight patients, 9.2%).

The age at presentation range from 3 weeks to 122 months (mean of 24 months). Ten patients (11.5%) presented above 5 years of age. The disease was unilateral in 57 (65.5%) and bilateral in 30 (34.5%) patients. Only one patient has a family history of Retinoblastoma. Figure 2 showed the ocular presentation of the disease.

The mean duration of symptoms before presentation was 4 months, with the range of 1 day to 36 months. Seventy-five percent (65 patients) presented within 6 months, 10.3% (nine patients) between 7 to 12 months while 6.9% (six patients) had the symptoms for more than 12 months before being seen at the referred center. Staging of the disease at diagnosis is presented in Table II. Six patients had orbital retinoblastoma while two patients had intracranial metastases at presentation.

Enucleation was performed in 85.1% of patients. Of the 74 enucleated eyes, 24 eyes (32.2%) showed 'high risk factors predictive of metastases' evident on histopathological examination. 51 (58.6%) patients had systemic chemotherapy whereas six (6.9%) patients had external beam radiotherapy.

Table I: International Intraocular Retinoblastoma Classification (IIRC)⁹

Group A - Small intraretinal tumours away from foveola and disc.

- All tumours are 3 mm or smaller in greatest dimension, confined to the retina and
- All tumours are located further than 3 mm from the foveola and 1.5 mm from the optic disc.

Group B - All remaining discrete tumours confined to the retina.

- All other tumours confined to the retina not in Group A.
- Tumour-associated subretinal fluid less than 3 mm from the tumour with no subretinal seeding.

Group C - Discrete local disease with minimal subretinal or vitreous seeding.

- Tumour(s) are discrete.
- Subretinal fluid, present or past, without seeding involving up to one-fourth of the retina.
- Local fine vitreous seeding may be present close to discrete tumour.
- Local subretinal seeding less than 3 mm (2 DD) from the tumour.

Group D - Diffuse disease with significant vitreous or subretinal seeding.

- Tumour(s) may be massive or diffuse.
- Subretinal fluid present or past without seeding, involving up to total retinal detachment.
- Diffuse or massive vitreous disease may include "greasy" seeds or avascular tumour masses.
- Diffuse subretinal seeding may include subretinal plaques or tumour nodules.

Group E - Presence of any one or more of these poor prognosis features.

- Tumour touching the lens.
- Tumour anterior to anterior vitreous face involving ciliary body or anterior segment.
- Diffuse infiltrating retinoblastoma.
- Neovascular glaucoma.
- Opaque media from hemorrhage.
- Tumour necrosis with aseptic orbital cellulites.
- Phthisis bulbi.

Table II: Classification of Retinoblastoma (IIRC)

	Number of eyes	%
Group A	5	4.3
Group B	5	4.3
Group C	10	8.5
Group D	18	15.4
Group E	73	62.4
Not Available	6	5.1
Total eyes	117	100

Recurrences of tumour were seen in seven eyes at the average of 15 months after diagnosis. The earliest recurrences were at five months and the latest at 24 months. Four patients eventually had bilateral enucleation after treatment failure in the one remaining eye. Fourteen patients (16.1%) were lost to follow-up. Death was reported in three patients, two of them had intracranial metastases at presentation and one had associated 13q deletion syndrome.

DISCUSSION

Retinoblastoma affects between one in 15,000 and 20,000 livebirths depending on the country. As only children developed retinoblastoma, the birth rate and infant mortality rate of a country are important to estimate the number of children that may be affected. In the United States it is estimated about 250-300 new cases diagnosed per year¹⁰. In Malaysia the exact incidence is unknown. Based on the 2009 census data for annual births in Malaysia, approximately 27 to 36 new cases are expected to be diagnosed each year. Hospital Kuala Lumpur, being the main tertiary center for Retinoblastoma in Malaysia, sees an average of 14.5 new cases per year.

Our findings showed that the spectrum of the presenting symptoms were similar to those reported elsewhere in which leucocoria was the most common presentation followed by strabismus (68.4% and 12.0% respectively). The disease was unilateral in 65.5% and bilateral in 34.5% of patients. Late presentation seems to be common in developing countries. This is observed in this study where diagnosis are made at older age with majority of patients presented in advanced stage of classification.

Chemotherapy with adjuvant local treatment are now an integral part of the current management of retinoblastoma. Two-thirds of our patients had systemic chemotherapy either as primary chemoreduction or as adjuvant therapy following enucleation. Given the late presentation of patients, enucleation still plays a major role in treatment of retinoblastoma with an enucleation rate of 85% of patients in this study.

Sixteen percent of the patients were lost to follow-up at various levels. Although there was no exact data on the cause of this, experience at this centre showed that most of them are at the initial phase due to refusal and inability to accept enucleation as a form of treatment. Some patients are lost in the middle of treatment because parents are unable to cope with the intensive treatment and frequency of the follow-ups. In most instances the issues are more of parental motivations rather than financial constraints as treatment for this childhood cancer are highly subsidised by the government and National Cancer Council (MAKNA).

There are limitations to this registry. Presently the data from this registry were only collected from a single treatment center. The data was analysed to give an overall view of

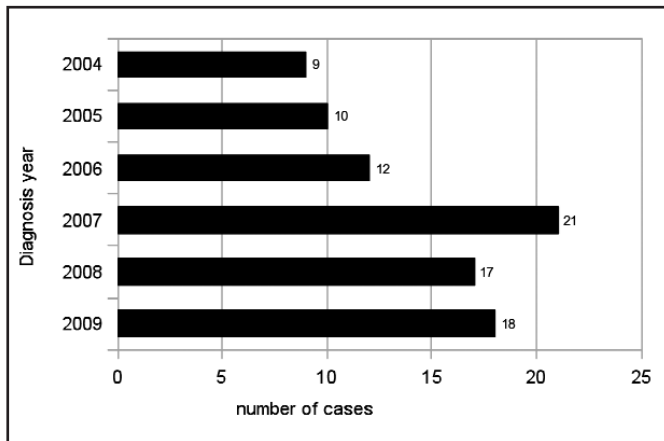


Fig. 1: Frequency of new patients per year

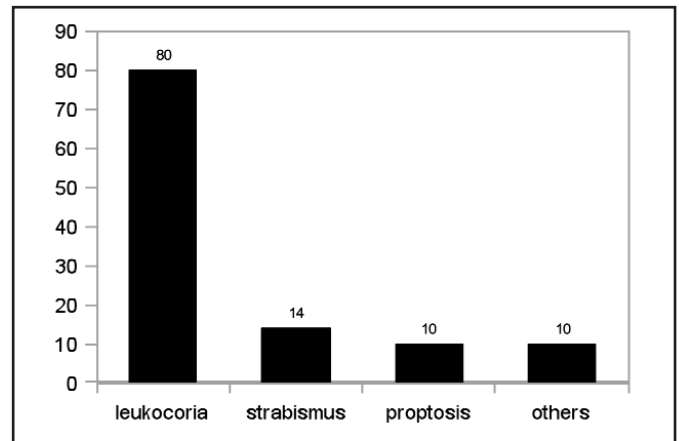


Fig. 2: Clinical presentation

retinoblastoma without differentiating the unilateral (non-hereditary) and bilateral (hereditary) disease. This study is relevant because the data obtained were from the country's national reference center. These preliminary findings reflected the retinoblastoma situation of the country. The problem of late diagnosis and presentation has to be tackled to improve prognosis and quality of life for these patients. These data demonstrated the need to develop an awareness programme for early detection, to decrease the number of patients with advanced extraocular disease and offer less aggressive treatment with better outcomes.

This registry will be open to other centres that manage retinoblastoma nationwide. These centres are the university hospitals (Pusat Perubatan Universiti Malaya, Pusat Perubatan Universiti Kebangsaan Malaysia and Hospital Universiti Sains Malaysia), Hospital Umum Sarawak in Kuching, Sarawak and Hospital Queen Elizabeth in Kota Kinabalu, Sabah. With participation of these centers, the actual impact of retinoblastoma to the country will be better understood.

It is our hope that with the development of this registry, and collaboration with all these centres, we can develop a national treatment protocol to enhance medical care to retinoblastoma patients. Treatment can be standardised so that every centre can offer the best available treatment and patients can be treated at the nearest centres without compromising care.

ACKNOWLEDGEMENT

We wish to thank the Director-General of Health of MOH for permission to publish this article.

REFERENCES

1. Leal-Leal, C, Flores-Rojo, M, Medina-Sanson A *et al*. A multicenter report from the Mexican Retinoblastoma Group. *Br J Ophthalmol* 2004; 88: 1074-77.
2. Ozdemir H, Tacyildiz N, Unal E *et al*. Clinical and epidemiological characteristics of retinoblastoma: correlation with prognosis in a Turkish pediatric oncology center. *Pediatr Hematol Oncol*. 2007; 24: 221-31.
3. Bhurgri Y, Muzaffar S, Ahmed R *et al*. Retinoblastoma in Karachi, Pakistan. *Asian Pac J Cancer Prev*. 2004; 5: 159-63.
4. Ozkan A, Pazarli H, Celkan T *et al*. Retinoblastoma in Turkey: survival and clinical characteristics 1981-2004. *Pediatr Int*. 2006; 48: 369-73.
5. Sitorus RS, Moll AC, Suhardjono S *et al*. The effects of therapy refusal against medical advice in retinoblastoma patients in a setting where treatment delays are common. *Ophthalmic Genet*. 2009; 30(1): 31-36.
6. Chang CY, Chiou TJ, Hwang B *et al*. Retinoblastoma in Taiwan: survival rate and prognostic factors. *Jpn J Ophthalmol* 2006; 50: 242-49.
7. Bekibebe CO, Ayede AI, Asaolu OO, Brown BJ. Retinoblastoma: the challenges of management in Ibadan, Nigeria. *J Pediatr Hematol Oncol*. 2009; 31: 552-55.
8. Goh PP, NorFariza N, Mariam I. National Eye Database- A web Based Surveillance System. *Med J Malaysia* 2008; 63.
9. Gallie BL, Erraguntla V, Heon E, Chan HSL. Retinoblastoma. In: Taylor D, Hoyt C, editors. *Pediatric Ophthalmology and Strabismus*. Philadelphia, PA: Saunders; 2004.
10. Gunduz K, Shields CL. Retinoblastoma Update. *Focal Points: Clinical Modules for Ophthalmologists*, Volume XXIII Number 7, September 2005.